

Supplementary materials

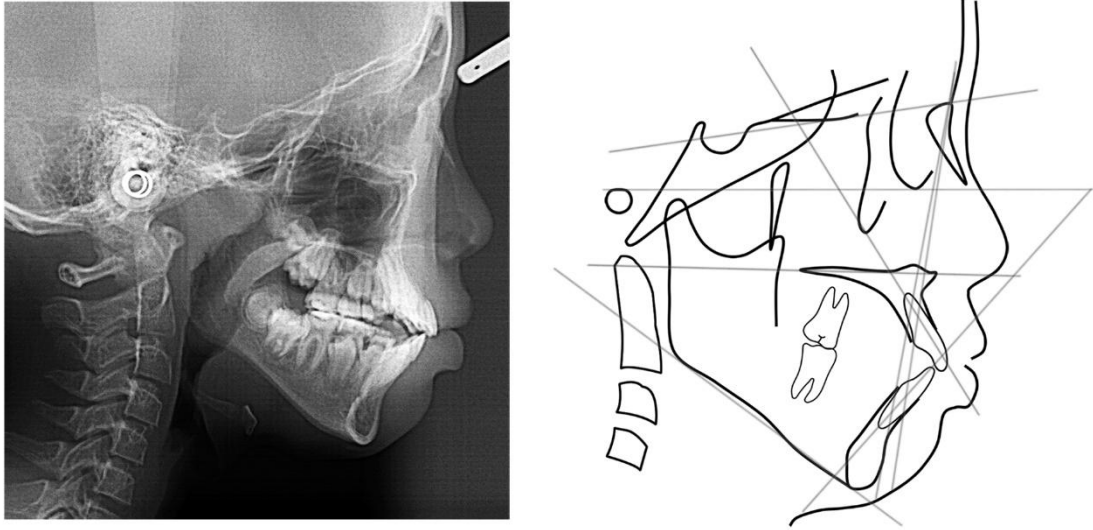


Figure S1. Lateral cephalometric radiographs and tracing after 18 months of FR-4 treatment.

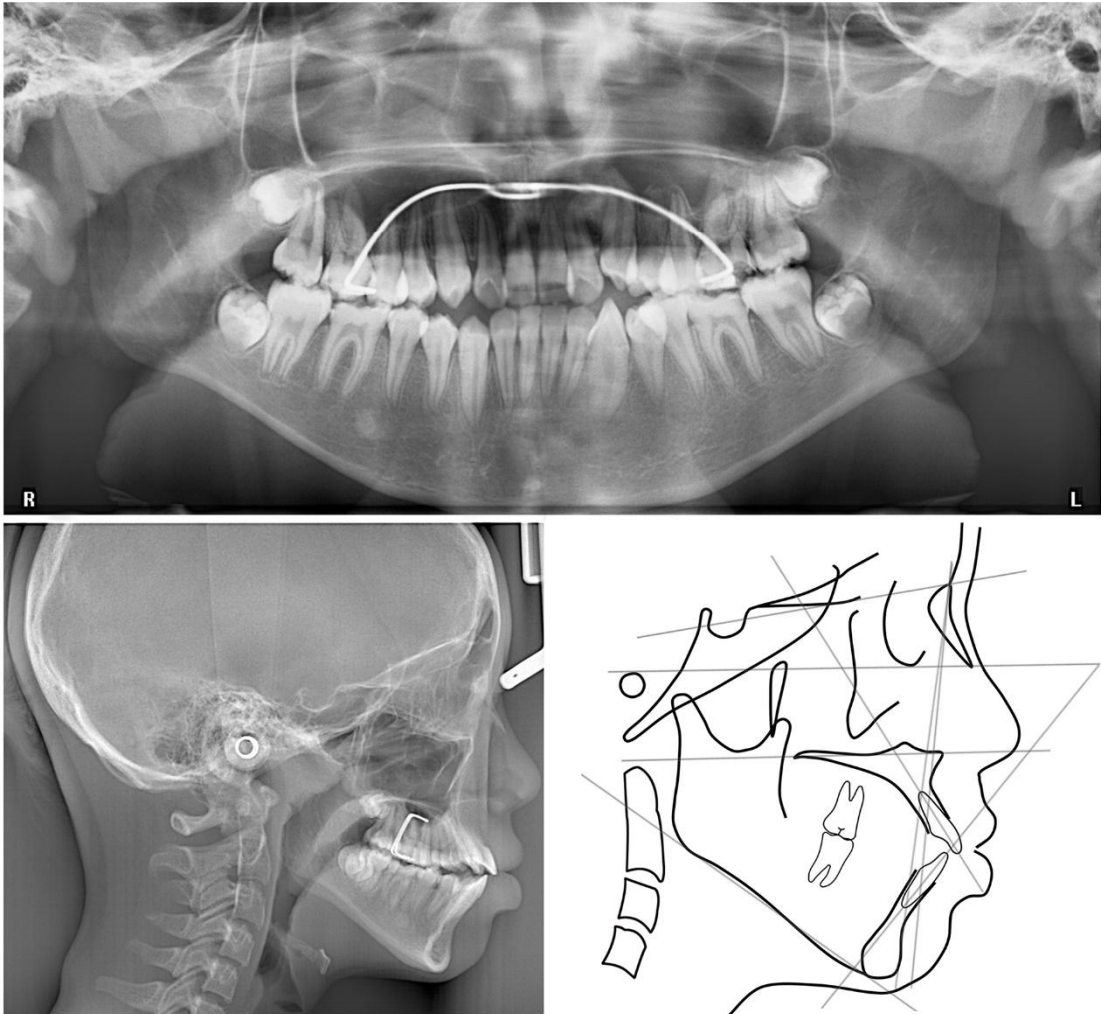


Figure S2. Posttreatment panoramic and lateral cephalometric radiographs and tracing after mSLBB treatment.

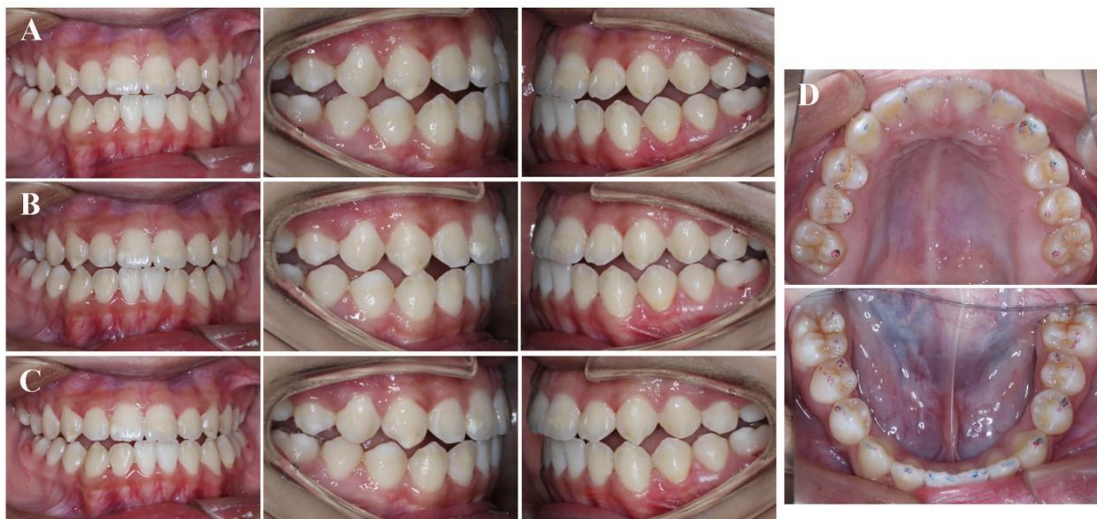

Figure S3. Assessment of functional occlusion:(A) protrusive movement. (B) right excursive movement. (C) left excursive movement. (D)occlusal marks; red: centric contact, blue: protrusive and lateral excursive movements of the mandible.